

## Effect of topical propolis and dexamethasone on the healing of oral surgical wounds

Lopes-Rocha R, MSc, Professor of Dental Prosthesis, Department of Dentistry, Federal University of Vales do Jequitinhonha e Mucuri (UFVJM), Diamantina, MG, Brazil

Miranda JL, PhD, Professor of Pathology; Lima NL, PhD, Professor of Pathology

Ferreira FO, PhD, Professor of Epidemiology; Santos AS, PhD, Professor of Biochemistry, Department of Basic Sciences, UFVJM, Diamantina, MG, Brazil

Marinho SA, PhD, Department of Pathology, Professor of Pathology, Universidade Estadual da Paraíba, Araruna, PB, Brazil

Verli FD, PhD, Professor of Pathology, Department of Basic Sciences of the UFVJM

Correspondence to: Flaviana Verli, e-mail: flavianaverli@gmail.com

Keywords: propolis, dexamethasone, wound healing, inflammation, tongue

### Abstract

**Background:** The aim of the study was to determine the effects of the topical administration of propolis and dexamethasone on oral surgical wounds.

**Method:** Surgical wounds were made on the dorsum of the tongues of 90 hamsters, which were then divided into three experimental groups. The wounds were submitted to topical applications of a 30% ethanolic extract of propolis (EEP) (Group 1), 0.1% dexamethasone in orabase gel (Group 2), and orabase gel alone (Group 3). Six animals from each subgroup were sacrificed on days 1, 3, 7, 14, and 28 post surgery. Statistical analysis, involving nonparametric Kruskal-Wallis and Mann-Whitney tests and a chi-square test, were used to compare categorical variables.

**Results:** The macroscopic exam of the surgical sites revealed statistically significant differences in the wound area between the propolis group and the remaining groups on day 7 postoperatively ( $p$ -value = 0.002). In the microscopic exam, the effects of EEP and dexamethasone were compared with regard to the presence of necrotic tissue, intensity of inflammation, formation of granulation tissue and epithelialisation.

**Conclusion:** In conclusion, our results showed that EEP demonstrated a greater anti-inflammatory effect and shorter healing time in oral surgical wounds in hamsters, in comparison to dexamethasone in orabase gel.

© Peer reviewed. (Submitted: 2011-12-29. Accepted: 2012-04-25.) © Medpharm

Wound Healing Southern Africa 2012;5(1):25-30

### Introduction

The healing of surgical wounds is a dynamic process that is characterised by the occurrence of inflammatory, proliferative and remodelling events.<sup>1-3</sup> Different substances were administered to accelerate or modulate the healing of surgical wounds, such as propolis and dexamethasone.<sup>4-8</sup>

Propolis-based products have been the object of research due to their immune-stimulating, antimicrobial, anti-inflammatory and healing properties.<sup>4-6,9</sup> The active ingredients in propolis are flavonoids, phenolic acids and their esters.<sup>10-12</sup> Despite reducing inflammation in the acute phase, dexamethasone also inhibits the synthesis of collagen fibres by fibroblasts in a subsequent phase of healing.<sup>7,13,14</sup> The healing properties of both substances have been investigated.<sup>6,7,9,14</sup> However, to the best of our knowledge, there have been no comparative histological analyses on the topical administration of propolis and dexamethasone in the healing of oral surgical wounds performed on an animal model.

The aim of the present study was to determine and compare the effects of the topical administration of propolis and dexamethasone on oral surgical wounds performed on hamsters through macroscopic and histopathological analyses.

### Method

#### Sample group

The protocol of this study was approved by the Animal Use Ethical Committee of the Federal University of Vales do Jequitinhonha e Mucuri (protocol 003/2010). Ninety male and female Syrian hamsters (*Mesocricetus auratus*) at 90 days of age, and weighing approximately 120 g, were kept in plastic cages (60 cm x 50 cm x 22 cm) lined with sterilised wood shavings, and maintained at room temperature (mean of 24°C) with a 12:12 hour light:dark photoperiod. The animals were provided with a balanced solid ration (Nuvilab CR1®, Nuvital, Colombo, Paraná, Brazil) and water ad libitum. After the period of acclimatisation, the animals were randomly distributed among three experimental groups, of 30 animals each.

#### Surgical wound procedure

All animals were anaesthetised with an intraperitoneal injection of xylazine (10 mg/kg) and ketamine (200 mg/kg). A surgical wound 4 mm in diameter, and 0.5 mm in depth, was performed on the dorsum of the tongue of each animal with the aid of a punch.

### Administration of substances

The topical administration of the substances was performed every 12 hours, using a number 1 camel hair brush (Tigre®, Sao Paulo, Brazil). Group 1 received a commercial 30% ethanolic extract of propolis (EEP) (Apiário Mackllani, Santa Bárbara, Minas Gerais, Brazil); Group 2 received 0.1% dexamethasone in orabase gel; and Group 3 received orabase gel alone. The substances were applied throughout the experiment, until each subgroup was sacrificed. The application consisted of four consecutive brushings, using no excess solution.

### Total polyphenol and flavonoid contents

Total polyphenol contents in the used EEP were determined by the Folin-Ciocalteu colorimetric method.<sup>15</sup> Diluted commercial EEP solution (0.5 ml) was mixed with 0.5 ml of the Folin-Ciocalteu reagent, and 0.5 ml of 10% Na<sub>2</sub>CO<sub>3</sub>, and the absorbance was measured at 760 nm after one hour incubation at room temperature. Total polyphenol contents were calculated as gallic acid equivalents present in dried ethanolic extract (mg/g). Total flavonoid contents in the extracts were determined using a method described by Park et al<sup>16</sup> with minor modifications. For this, 0.5 ml of EEP solution, 4.3 ml of 80% methanol, 0.1 ml of 10% Al(NO<sub>3</sub>)<sub>3</sub> and 0.1 ml of 1 M potassium acetate was added. After 40 minutes at room temperature, the absorbance was measured at 415 nm. Total flavonoid contents were calculated as quercetin equivalent (mg/g) from a calibration curve.

### Euthanasia procedure

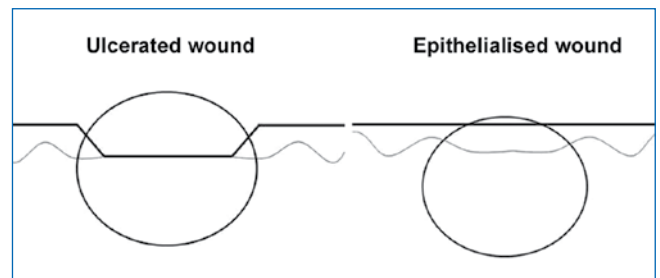
Subgroups of six animals from all groups were sacrificed on days 1, 3, 7, 14, and 28, following the execution of the surgical wounds. The animals were duly anaesthetised with an intraperitoneal injection of xylazine (10 mg/kg) and ketamine (200 mg/kg), mixed in the same syringe. The animals were decapitated, and the heads were immediately submerged in a 10% buffered formaldehyde solution for 48 hours. The tongues were then dissected, and separated from the heads.

### Macroscopic analysis

During the macroscopic exam, two measurements were made of the diameters of the surgical wounds using a caliper. Assuming “x” to be the measurement of the diameter in the lateral-lateral direction, and “y” to be the measurement of the diameter in the anterior-posterior direction, the wound area was calculated as  $A = \pi \cdot x/2 \cdot y/2$ , with  $\pi = 3.1416$ .

### Histopathological analysis

The tips of the tongues were cut transversally such that the cut passed through the middle of the wound for the histopathological analysis. Fragments were embedded in paraffin to obtain histological cuts 5 µm in thickness, and stained with hematoxylin and eosin (HE). The specimens were duly separated in accordance with the postoperative subgroups (days 1, 3, 7, 14 and 28). The histopathological analysis was performed to determinate the presence of necrotic tissue, acute



**Figure 1:** Histological field on slides in which variables were analysed on ulcerated and epithelialised wounds

and chronic inflammatory infiltration, formation of granulation tissue and epithelialisation. The following scores were used: 0 = variable absent; 1 = mild presence of variable; 2 = moderate presence; and 3 = intense presence. The field for the histological analysis was the central area of the wound (Figure 1). For this, a light microscope (Olympus® BX 41, Olympus, Shinjuku-Ku, Tokyo, Japan) was used at a magnification of 100, 200, and 400 ×.

### Statistical analysis

The Kolmogorov-Smirnov test revealed that data did not present normal distribution. Comparisons between data of macroscopic examination were performed using the Kruskal-Wallis and the Mann-Whitney test for pairwise comparison, taking into account the Bonferroni adjustment for multiple comparisons. The microscopic data analysis was submitted to a chi-square test. The level of significance was set at p-value = < 0.05, with Bonferroni correction when necessary (multiple comparisons).

### Results

The macroscopic analysis of the surgical wounds revealed no clinical signs of secondary infection. The Kruskal-Wallis test revealed a statistically significant difference in ulcerated areas mean between the groups on day 7 postoperatively. In pairwise analysis, using the Mann-Whitney test, and taking into account the Bonferroni adjustment (p-value = < 0.016), significant differences were found between Group 1 and Group 2 (p-value = 0.002) (Table I).

Histopathological analysis revealed a significant difference in the presence of necrotic tissue between groups on days 1, 3 and 7 postoperatively, with the observation that Group 1 always showed lower values compared with the other groups. In pairwise analysis between Group 1 and Group 2 on day 1 postoperatively, there were no significant differences (p-value = 0.019), when taking the Bonferroni adjustment into consideration (p-value = < 0.0083). There were significant differences on day 3 postoperatively (p-value = 0.002), and on day 7 postoperatively (p-value = 0.002) (Table II).

The acute inflammatory infiltration was intense in all groups on day 1. On day 3, the acute inflammatory infiltrate decreased in 50% of the wounds of the animals in Group 1. In the other groups, in all the animals, the acute inflammation remained intense, which was statistically significant different (p-value = 0.027). However, when

**Table I:** Median ulcerated area (mm<sup>2</sup>) of surgical wounds in propolis (Group 1), dexamethasone (Group 2) and orabase (Group 3) groups at different postoperative times

Groups	Median ulcerated area of wound in mm <sup>2</sup> (Group 1-Group 3: first quartile to second quartile)				
	Day 1	Day 3	Day 7	Day 14	Day 28
Propolis (Group 1)	6.33 (4.23-7.22)	6.57 (5.90-7.87)	0 <sup>a</sup>	0	0
Dexamethasone (Group 2)	5.67 (4.18-5.98)	6.70 (5.89-7.41)	4.4 (1.25-4.56) <sup>a</sup>	0	0
Orabase (Group 3)	4.82 (4.59-5.98)	5.81 (5.03-6.77)	2.26 (1.29-2.44)	0	0
p-value <sup>a</sup>	0.629 <sup>b</sup>	0.278 <sup>b</sup>	0.002 <sup>b</sup>	1.00 <sup>b</sup>	1.00 <sup>b</sup>

a = Mann-Whitney test for Group 1 and Group 2 comparison, p-value = 0.002; b = Kruskal-Wallis test for intergroups comparison, p-value = < 0.05

**Table II:** Distribution of scores of necrotic tissue at different postoperative evaluation times in propolis (Group 1), dexamethasone (Group 2) and orabase (Group 3) groups

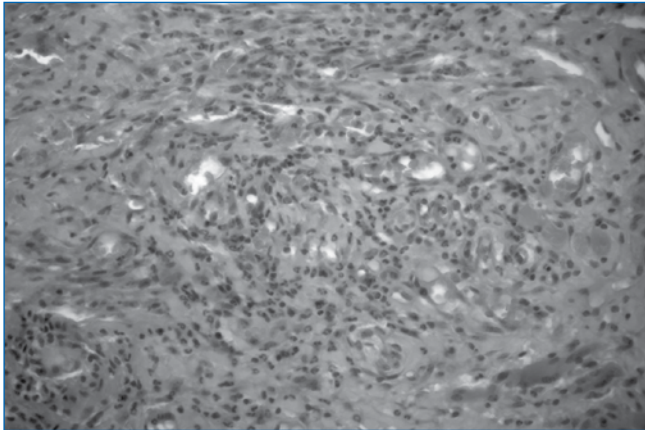
Necrotic tissue scores	Day 1			Day 3			Day 7		
	Group 1 n (%)	Group 2 n (%)	Group 3 n (%)	Group 1 n (%)	Group 2 n (%)	Group 3 n (%)	Group 1 n (%)	Group 2 n (%)	Group 3 n (%)
Absent	5 (83.3)	0	0	3 (50)	0	0	6 (100)	0	0
Low	1 (16.7)	1 (16.7)	0	3 (50)	0	3 (50)	0	0	6 (100)
Moderate	0	1 (16.7)	4 (66.7)	0	6 (100)	2 (33.3)	0	6 (100)	0
High	0	4 (66.7)	2 (33.3)	0	0	1 (16.7)	0	0	0
p-value	Group 1 x Group 2 = 0.019 <sup>a</sup>			Group 1 x Group 2 = 0.002 <sup>b</sup>			Group 1 x Group 2 = 0.002 <sup>c</sup>		
p-value	Group 1 x Group 2 x Group 3 = 0.003 <sup>d</sup>			Group 1 x Group 2 x Group 3 = 0.006 <sup>d</sup>			Group 1 x Group 2 x Group 3 = < 0.001 <sup>d</sup>		

a = Bonferroni correction for significant p-value = < 0.0083; b = chi-square significant values with Bonferroni correction in p-value = < 0.016; c = Fisher test significant values, d = chi-square test significant values

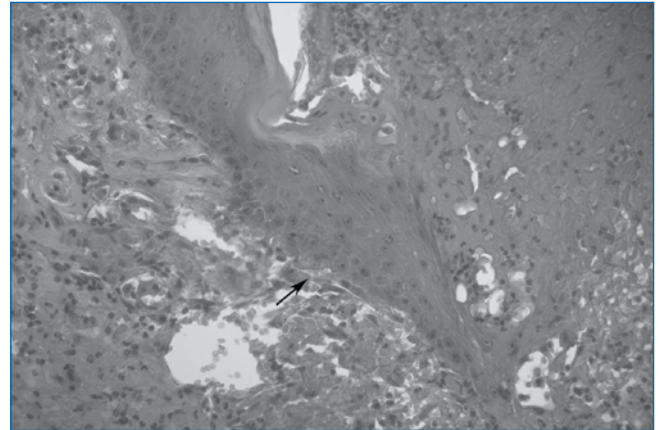
**Table III:** Distribution of scores of acute and chronic inflammation at different postoperative evaluation times in propolis (Group 1), dexamethasone (Group 2) and orabase (Group 3) groups

Acute inflammation	Day 1			Day 3			Day 7		
	Groups			Groups			Groups		
	Group 1 n (%)	Group 2 n (%)	Group 3 n (%)	Group 1 n (%)	Group 2 n (%)	Group 3 n (%)	Group 1 n (%)	Group 2 n (%)	Group 3 n (%)
Absent	0	0	0	0	0	0	6 (100)	6 (100)	6 (100)
Low	0	0	0	0	0	0	0	0	0
Moderate	1 (16.7)	0	0	3 (50)	0	0	0	0	0
High	5 (83.3)	6 (100)	6 (100)	3 (50)	6 (100)	6 (100)	0	0	0
p-value				Group 1 x Group 2 = 0.091 <sup>a</sup>					
p-value	Group 1 x Group 2 x Group 3 = 0.347			Group 1 x Group 2 x Group 3 = < 0.027 <sup>b</sup>			Group 1 x Group 2 x Group 3 = 1.00		
Chronic inflammation	Day 3			Day 7			Day 14		
	Groups			Groups			Groups		
	Group 1 n (%)	Group 2 n (%)	Group 3 n (%)	Group 1 n (%)	Group 2 n (%)	Group 3 n (%)	Group 1 n (%)	Group 2 n (%)	Group 3 n (%)
Absent	6 (100)	6 (100)	6 (100)	6 (100)	0	0	6 (100)	6 (100)	6 (100)
Low	0	0	0	0	0	5 (83.3)	0	0	0
Moderate	0	0	0	0	6 (100)	1 (16.7)	0	0	0
High	0	0	0	0	0	0	0	0	0
p-value				Group 1 x Group 2 = 0.002 <sup>c</sup>					
p-value	Group 1 x Group 2 x Group 3 = 1.00			Group 1 x Group 2 x Group 3 = < 0.001 <sup>b</sup>			Group 1 x Group 2 x Group 3 = 1.00		

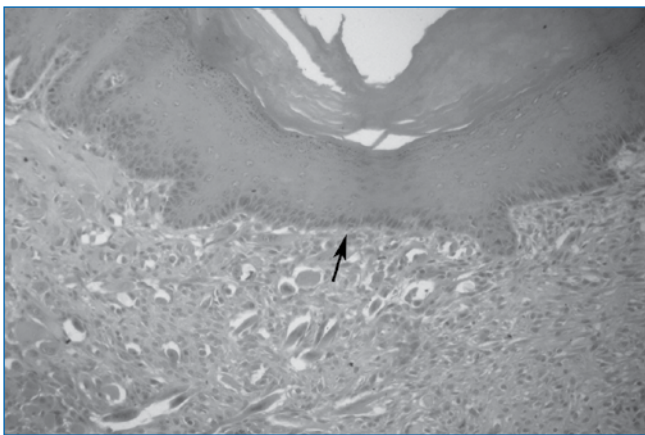
a = Fisher test value; b = chi-square test significant values; c = Fisher test significant value



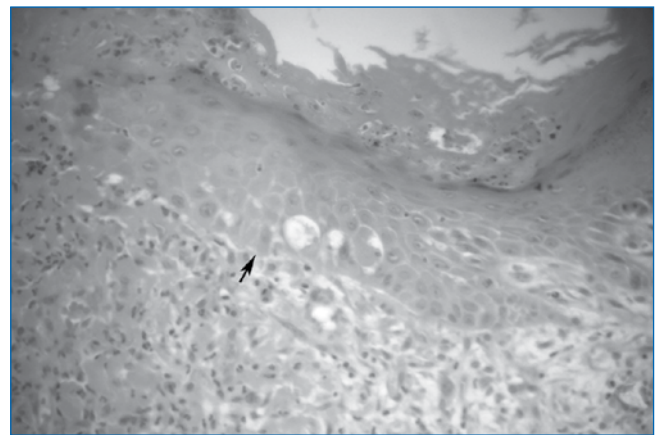
**Figure 2:** Granulation tissue in wound in the propolis group on day 3 post-operatively (400x, hematoxylin and eosin)



**Figure 3:** Beginning of epithelialisation (arrow) in wound in propolis group on day 3 (400 x, hematoxylin and eosin)



**Figure 4:** Total epithelialisation (arrow) in wound in propolis group on day 7 (200 x, hematoxylin and eosin)



**Figure 5:** Partial epithelialization (arrow) in wound in dexamethasone group on day 7 (400 x, hematoxylin and eosin)

**Table IV:** Distribution of scores of granulation tissue and epithelialisation at the different postoperative evaluation times in propolis (Group 1), dexamethasone (Group 2) and orabase (Group 3) groups

Granulation tissue	Day 1			Day 3			Day 7		
	Groups			Groups			Groups		
	Group 1 n (%)	Group 2 n (%)	Group 3 n (%)	Group 1 n (%)	Group 2 n (%)	Group 3 n (%)	Group 1 n (%)	Group 2 n (%)	Group 3 n (%)
Absent	0	0	0	0	0	0	0	0	0
Low	6 (100)	6 (100)	6 (100)	0	3 (50)	0	0	0	0
Moderate	0	0	0	2 (40)	3 (50)	0	0	0	0
High	0	0	0	4 (40)	0	6 (100)	6 (100)	6 (100)	6 (100)
p-value				Group 1 x Group 2 = 0.027 <sup>a</sup>					
p-value	Group 1 x Group 2 x Group 3 = 1.00 <sup>b</sup>			Group 1 x Group 2 x Group 3 = < 0.006 <sup>b</sup>			Group 1 x Group 2 x Group 3 = 1.00		
Epithelialisation	Day 3			Day 7			Day 14		
	Groups			Groups			Groups		
	Group 1 n (%)	Group 2 n (%)	Group 3 n (%)	Group 1 n (%)	Group 2 n (%)	Group 3 n (%)	Group 1 n (%)	Group 2 n (%)	Group 3 n (%)
Absent	0	6 (100)	2 (33.3)	0	4 (66.7)	0	0	0	0
Low	6 (100)	0	4 (66.7)	0	2 (33.3)	0	0	0	0
Moderate	0	0	0	0	0	6 (100)	0	0	0
High	0	0	0	6 (100)	0	0	6 (100)	6 (100)	6 (100)
p-value	Group 1 x Group 2 = 0.002 <sup>a</sup>			Group 1 x Group 2 = 0.002 <sup>c</sup>					
p-value	Group 1 x Group 2 x Group 3 = 0.002 <sup>b</sup>			Group 1 x Group 2 x Group 3 = < 0.001 <sup>b</sup>			Group 1 x Group 2 x Group 3 = 1.00		

a = Fisher test significant value; b = chi-square test significant values; c = chi-square test significant value with Bonferroni correction p-value = <0.016

analysing the groups by pairwise Fisher's exact test, no significant difference between Group 1 and Group 2 was found ( $p$ -value = 0.091) (Table III).

The chronic inflammatory infiltration was absent on day 1 and 3 after surgery. On day 7, there were significant differences among all groups. In pairwise analysis, Fisher's test showed significant differences between Groups 1 and 2 ( $p$ -value = 0.002) (Table III).

The formation of granulation tissue began on day 3 (Figure 2), and was similar (mild) in all three groups. However, on day 7, there was a significant difference between the groups ( $p$ -value = 0.006). In the comparison between Group 1 and Group 2 ( $p$ -value = 0.027), the differences were close to significance, when taking into consideration the Bonferroni correction of  $p$ -value = < 0.016) (Table IV and Figure 2).

The re-epithelialisation began on day 3, and was significantly different between the groups on day 3 postoperatively ( $p$ -value = 0.002), and day 7 postoperatively ( $p$ -value < 0.0001). When comparing Groups 1 and 2, there were significant differences on day 3 postoperatively ( $p$ -value = 0.002, Fisher's exact test) (Figure 3); and on day 7 postoperatively ( $p$ -value = 0.002), with Bonferroni correction  $p$ -value = < 0.016) (Figure 4 and Figure 5). From day 14, there was a resemblance of this variable in all the groups (Table IV).

## Discussion

The process of wound repair has been performed on hamsters' tongues,<sup>17</sup> and on other types of mice, because of tissue and anatomical<sup>18,19</sup> similarities to the human tongue. Therefore, the present study was conducted in hamsters.

Propolis has been administered either topically or systemically in different vehicles, such as alcohol, propylene glycol and water, with the aim of modulating the healing of surgical wounds.<sup>4,9,10,20</sup> In the present study, propolis was administered topically, as this substance has the capacity to penetrate the wound. This penetration capacity was demonstrated in a study by Sehn et al,<sup>4</sup> using photoacoustic spectroscopy. Studies by Gulinelli et al<sup>9</sup> and Temiz et al<sup>20</sup> have demonstrated that the vehicle that is employed does not alter the effects of propolis. An alcohol vehicle was used in the present study. However, the use of an aqueous extract has been indicated for propolis.<sup>10</sup>

In this study, the presence of necrotic tissue in Group 1 was significantly lower when compared with that in Group 2, on days 3 and 7 postoperatively. According to Temiz et al,<sup>20</sup> this reduction in the necrotic tissue is due to the antibacterial properties of propolis. According to Park et al,<sup>21</sup> flavonoids that are present in propolis, such as galangin and pinocembrine, inhibit the activity of the bacterial glycosyltransferase. Therefore, they promote the reduction of its energy reserves. This may have contributed to the lowest amount of necrotic tissue in the propolis group.

On day 3, the wounds that were treated with EEP exhibited acute inflammation of a significantly lesser intensity than that in the other groups. The anti-inflammatory effects of propolis are associated with its chemical components, which vary depending on its origin and harvesting time.<sup>22,11</sup> According to Paulino et al,<sup>22</sup> artepillin-c, which is the main active ingredient in propolis that derives from southern Brazil, has an anti-inflammatory effect that is triggered by mechanisms associated with the inhibition of leukocyte activity. The authors state that the anti-inflammatory action of artepillin-c stems from the inhibition of nuclear factor kappa B, the reduction of prostaglandin E2, and the production and inhibition of nitric oxide production. According to Fässler et al,<sup>23</sup> when administered subcutaneously, dexamethasone inhibits leukocyte migration. In the wounds that were treated topically with dexamethasone (Group 2), acute inflammatory infiltration was intensive on day 3, and similar to that in the orabase gel group (Group 3), suggesting that 0.1% dexamethasone has late-onset anti-inflammatory action.

When the acute inflammation progressed to the chronic form, there was a predominance of a mononuclear infiltrate in the wounds of all the groups, comprising cells that were responsible for phagocytosis, and the release of growth factors that stimulate the synthesis of granulation tissue.<sup>6,20</sup> Therefore, it is suggested that the reduction in the acute inflammation in Group 1 was due to the action of its chemical components on macrophage populations.<sup>22</sup> According to Kilicoglu et al,<sup>24</sup> the reduction in acute inflammatory exudate stimulates the early activity of macrophages and TCD4 lymphocytes.

Beule et al<sup>25</sup> found that dexamethasone inhibited the formation of granulation tissue following nasal cartilage surgery, thereby avoiding the recurrence of stenosis. According to our test results, the formation of granulation tissue was more rapid on day 7 in Group 1 and Group 3, than in Group 2.

The EEP had induced the proliferation of keratinocytes, thereby accelerating the epithelialisation process, started earlier, from day 3 postoperatively, and completed on day 7 postoperatively, which was significantly faster than Groups 2 and 3. In these groups, 14 days were required for completion. These findings corroborate those that were reported by Temiz et al.<sup>20</sup> However, Xie et al<sup>14</sup> reported that dexamethasone did not inhibit the proliferation of keratinocytes in rats with the absence of the expression of the epithelial receptor for integrin  $\alpha v \beta 6$ . The findings of the present study are in agreement with those described by Sehn et al,<sup>4</sup> who found that topical administration of propolis stimulated the proliferation of keratinocytes, but without causing a retraction of the wound. When treating wounds with caffeic acid phenethyl ester, which is a component of propolis, Serarslan et al<sup>12</sup> reported an increase in healing and epithelialisation rates. McLennan et al<sup>6</sup> reported similar results, after administering propolis to wounds that were having difficulty healing in rats with induced diabetes.

## Conclusion

In conclusion, surgical wounds in the oral mucosa of hamsters treated with EEP exhibited a smaller area of ulceration, a reduction in inflammatory response, early formation of granulation tissue, and faster epithelialisation, when compared to those treated with dexamethasone. More detailed, in-depth studies should be carried out with the aim of investigating and isolating each active component of propolis, to determine its action in different vehicles of application.

## Conflict of interest

The authors declare that they have no conflict of interest.

## Acknowledgements

We would like to thank Leonardo da Cunha Monteiro, from the Laboratory of Pathology at the Federal University of Vales do Jequitinhonha e Mucuri, for technical support. This research was supported by the Fundação de Amparo à Pesquisa do Estado de Minas Gerais / FAPEMIG, (CDS 00186/06).

## References

- Espinosa L, Sosnik A, Fontanilla MR. Development and preclinical evaluation of acellular collagen scaffolding and autologous artificial connective tissue in the regeneration of oral mucosa wounds. *Tissue Eng Part A*. 2010;16(5):1667-1679.
- Gonzaga-Ribeiro MA, Cavalcanti de Albuquerque RL, Santos Barreto AL, et al. Morphological analysis of second-intention wound healing in rats submitted to 16 J/cm<sup>2</sup> lambda 660-nm laser irradiation. *Indian J Dent Res*. 2009;20(3):390.
- Desmoulière A, Redard M, Darby I, Gabbiani G. Apoptosis mediates the decrease in cellularity during the transition between granulation tissue and scar. *Am J Pathol*. 1995;146(1):56-66.
- Sehn E, Hernandez L, Franco SL, et al. Dynamics of reepithelialisation and penetration rate of a bee propolis formulation during cutaneous wounds healing. *Anal Chim Acta*. 2009;635(1):115-120.
- Moura SA, Ferreira MA, Andrade SP, et al. Brazilian green propolis inhibits inflammatory angiogenesis in a murine sponge model. *Evid Based Complement Alternat Med*. 2009 [epub ahead of print] [homepage on the Internet]. c2011. Available from: <http://www.ncbi.nlm.nih.gov/pmc/articles/PMC3094767/pdf/ECAM2011-182703.pdf>
- McLennan SV, Bonner J, Milne S, et al. The anti-inflammatory agent propolis improves wound healing in a rodent model of experimental diabetes. *Wound Repair Regen*. 2008;16(5):706-713.
- Oishi Y, Fu ZW, Ohnuki Y, et al. Molecular basis of the alteration in skin collagen metabolism in response to in vivo dexamethasone treatment: effects on the synthesis of collagen type I and III, collagenase, and tissue inhibitors of metalloproteinases. *Br J Dermatol*. 2002;147(5):859-868.
- Kylmäniemi M, Oikarinen A, Oikarinen K, Salo T. Effects of dexamethasone and cell proliferation on the expression of matrix metalloproteinases in human mucosal normal and malignant cells. *J Dent Res*. 1996;75(3):919-926.
- Gulinelli JL, Panzarini SR, Fattah CM, et al. Effect of root surface treatment with propolis and fluoride in delayed tooth replantation in rats. *Dent Traumatol*. 2008;24(6):651-657.
- Moura SA, Negri G, Salatino A, et al. Aqueous extract of Brazilian green propolis: primary components, evaluation of Inflammation and wound healing by using subcutaneous implanted sponges. *Evid Based Complement Alternat Med*. 2009 [epub ahead of print] [homepage on the Internet]. c2011. Available from: <http://www.ncbi.nlm.nih.gov/pmc/articles/PMC3137525/pdf/ECAM2011-748283.pdf>
- Teixeira EW, Message D, Negri G, et al. Seasonal variation, chemical composition and antioxidant activity of Brazilian propolis samples. *Evid Based Complement Alternat Med*. 2010;7(3):307-315.
- Serarslan G, Altug E, Kontas T, et al. Caffeic acid phenethyl ester accelerates cutaneous wound healing in a rat model and decreases oxidative stress. *Clin Exp Dermatol*. 2007;32(6):709-715.
- Chang SW, Chou SF, Yu SY. Dexamethasone reduces mitomycin C-related inflammatory cytokine expression without inducing further cell death in corneal fibroblasts. *Wound Repair Regen*. 2010;18(1):59-69.
- Xie Y, Gao K, Häkkinen L, Larjava HS. Mice lacking beta6 integrin in skin show accelerated wound repair in dexamethasone impaired wound healing model. *Wound Repair Regen*. 2009;17(3):326-339.
- Singleton VL, Orthofer R, Lamuela-Raventos RM. Analysis of total phenols and other oxidation substrates and antioxidants by means of Folin-Ciocalteu reagent. *Methods Enzymol*. 1999;299:152-178.
- Park YK, Koo MH, Sato HH, Contado JL. Survey of some components of propolis which were collected by *Apis mellifera* in Brazil. *Arqui Biol Tecnol*. 1995;38:1253-1259.
- Morosolli AR, Veeck EB, Niccoli-Filho W, et al. Healing process after surgical treatment with scalpel, electrocautery and laser radiation: histomorphologic and histomorphometric analysis. *Lasers Med Sci*. 2010;25(1):93-100.
- Kim J, Hadlock T, Cheney M, et al. Muscle tissue engineering for partial glossectomy defects. *Arch Facial Plast Surg*. 2003;5(5):403-407.
- Iwasaki S, Yoshizawa H, Kawahara I. Ultrastructural study of the relationship between the morphogenesis of filiform papillae and the keratinisation of the lingual epithelium in the rat. *J Anat*. 1999;195(Pt 1):27-38.
- Temiz M, Aslan A, Canbolant E, et al. Effect of propolis on healing in experimental colon anastomosis in rats. *Adv Ther*. 2008;25(2):159-167.
- Park YK, Koo MH, Abreu JA, et al. Antimicrobial activity of propolis on oral microorganisms. *Curr Microbiol*. 1998;36(1):24-28.
- Paulino N, Abreu SR, Uto Y, et al. Anti-inflammatory effects of a bioavailable compound, Artepillin C, in Brazilian propolis. *Eur J Pharmacol*. 2008;587(1-3):296-301.
- Fässler R, Sasaki T, Timpl R, et al. Differential regulation of fibulin, tenascin-C, and nidogen expression during wound healing of normal and glucocorticoid-treated mice. *Exp Cell Res*. 1996;222(1):111-116.
- Kilicoglu SS, Kilicoglu B, Erdemli E. Ultrastructural view of colon anastomosis under propolis effect by transmission electron microscopy. *World J Gastroenterol*. 2008;14(30):4763-4770.
- Beule AG, Scharf C, Biebler KE, et al. Effects of topically applied dexamethasone on mucosal wound healing using a drug-releasing stent. *Laryngoscope*. 2008;118(11):2073-2077.